

Why can't my baby breastfeed: The effects of an abnormal maxillary frenum attachment

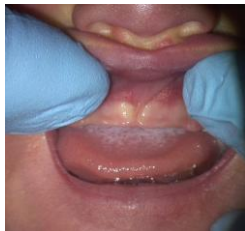
While tongue-tie is the most common cause of nursing difficulties that may result in both infants and mothers not having effective and enjoyable nursing, there is another part of the oral structures that can also contribute to latch problems. Inside the center of the upper lip is a small membrane between the lips and the gums that is called the **maxillary labial frenum**. When you look at this tissue, it actually is an attachment of the upper lip directly to the oral mucosa. It is does not function in any useful fashion and when revised is of little future significance. When it is attached very tightly and into the area where the teeth will eventually erupt or into the small area known as the *anterior papilla, it may also be a contributing factor in preventing a breastfeeding infant from developing a good latch while trying to flange his or her lips widely during breastfeeding. An infant may purse them instead, resulting in a shallower ineffective latch resulting in the failure to attach adequately to the upper areola area.

Future problems that may also develop and which the maxillary labial frenum may be a contributing factor includes: dental decay on the upper front teeth, gaps (diastemas) between the two front teeth, orthodontic or periodontal problems later in the child's oral development, poor lip mobility or function, especially during smiling and speaking. The maxillary (upper lip) frenum restrictions may occur by themselves or in conjunction with tongue-ties and can easily be revised without the need for the operating room or general anesthesia.

All too often parents complain then the lingual and or maxillary frenum are not diagnosed early as possible causes for their inability to comfortably and effectively breastfeed. To quote one parent. " It is very annoying as the tongue tie wasn't found until he was 4 weeks and after a nightmare few weeks of breastfeeding, Once diagnosed though, it was such a quick and easy thing to get snipped". All too often the maxillary frenum is also ignored and even with the tongue-tie revised, breastfeeding is still uncomfortable.

Those individuals who state most abnormal frenum attachments will resolve or go away by themselves are incorrect. The result is continued pain for moms and eventually infants giving up nursing. These frenum attachments may contribute to breastfeeding problems and should be evaluated for revision along with the lingual frenum revision for breastfeeding problems. (Additional peer reviewed articles published by Dr.Kotlow are available on his website)

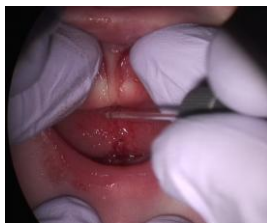Kotlow classification of infant maxillary frenum attachment



Class II

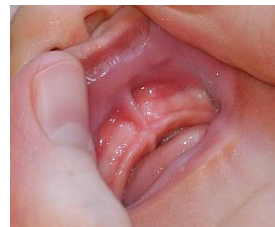Attaches mostly into the gingival tissue

* (papilla is the small bump of tissue just behind the area where the upper front teeth will erupt)



Class III

attaches just in front of the anterior papilla*

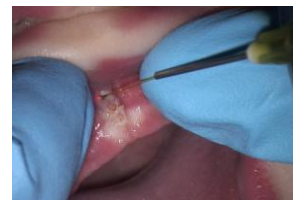
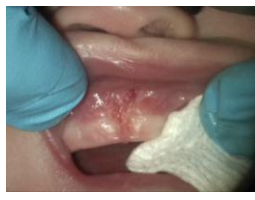
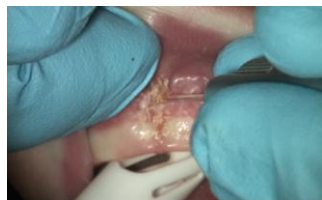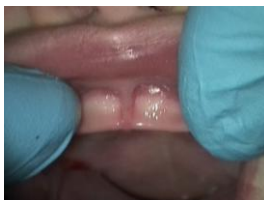Class IV

attachment into papilla* extending into the hard palate

Surgical revision of the maxillary labial frenum

The abnormal lip attachment or frenum is easily and safely revised using either a Diode laser or Erbium:YAG laser. In newborn infants there is usually no local anesthesia required, in some instances a topical anesthetic is applied for about 1 minute and the attachment is revised. In older infants a small amount of a local anesthetic may be used. *There is no need for any infant to be placed in the operating room or to have a general anesthetic.*

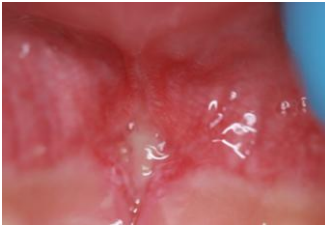

Class IV frenum

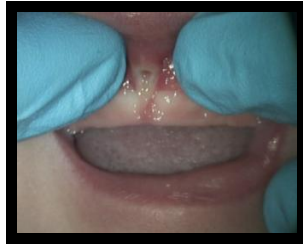revision using Erbium:YAG laser

immediate post surgery

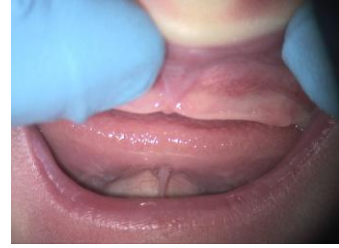revision using diode laser



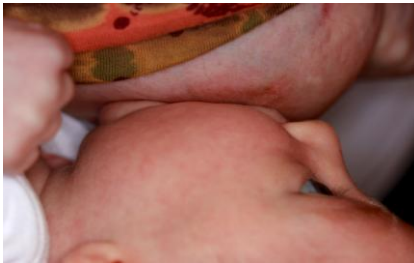White diamond appearance
4-5 days post surgery



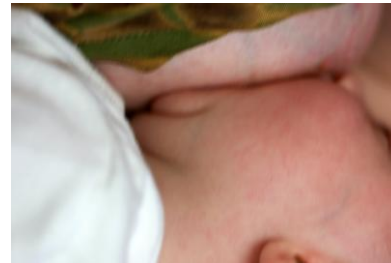* *elevating and pulling the upper lip
apart 2x daily



Abnormal lingual and maxillary
frenum in the same infant



**Poor latch due to upper lip
not getting good attachment**



Latch improvement after frenectomies

Post surgical care

- 1.* *At least 2x a day it is important to pull the upper lip upward opening the area of surgery so it will not reattach. Failure of doing this may result in the two areas of healing tissue to mend together.
2. Some swelling may occur depending on the depth of the surgical area, this is normal and should resolve in 24-36 hours. Placing ice over the area may provide some relief.
3. If you feel your infant is uncomfortable Tylenol or a similar pain medication may be used
4. Topical teething gels may also be applied
5. If you feel it is important to reach Dr.Kotlow you do not need to go through his office after hours service, you may reach him by calling him directly on his private cell phone. 518 369 7075.

Additional references and specialists

Wiessinger, D. and Miller, M. Breastfeeding difficulties as a result of tight lingual and labial frena: a case report. *J Hum Lact* 1995 Dec;

**Kotlow, I *J Hum Lact Online* First, published on March 22, 2010 as
doi:10.1177/0890334410362520 111(4): 313-6.**

The Influence of the Maxillary Frenum on the Development and Pattern of Dental Caries on Anterior Teeth in Breastfeeding Infants: Prevention, Diagnosis, and Treatment

Catherine Watson Genna New York City NY USA From: *LEAVEN*, Vol. 38 No. 2, April-May 2002, pp. 27-29.

Brian Palmer, D.D.S ;see on line PowerPoint presentation